

Multiple Keratoacanthoma Responsive to Acitretin in an Old Man with Depressed Mood

Mojtaba Babaei Zarch ^{1,*}, Fariba Binesh ¹, Narges Ghanei ¹

¹ School of Medicine, Shahid Sadoughi University of Medical Sciences, Yazd, Iran

* Corresponding author: Mojtaba Babaei Zarch, School of Medicine, Shahid Sadoughi University of Medical Sciences, Yazd, Iran. E-mail: mojtaba.babaei72@yahoo.com

DOI: 10.21859/focsci-03041418

Submitted: 02.11.2017

Accepted: 05.27.2017

Keywords:

Keratoacanthoma

Neoplasms

Acitretin

© 2017. Focus on Sciences

Abstract

Introduction: Keratoacanthoma (KA) is a common neoplasm and one of variety squamous cell carcinoma (SCC) characterized by rapid growth with potential for tissue damage.

Case Presentation: A 64-year-old man presented with hyperkeratotic papules that initially appeared on the dorsum of his hand and slowly progressed to form a large annular plaque along with multiple small keratotic plaques and papules. He was depressed and worried about the appearance and lesions. He had a history of multiple surgery on the lesions that had recurrence and finally the surgeon decided to do extensive excision with flap that had recurrence on the donor and recipient site, too. Treatment with Acitretin was started. Evolution of new lesions had decreased and stable lesions had begun to regress.

Conclusions: Although the gold standard for the treatment of keratoacanthoma is surgical excision, oral retinoid can be a good choice for multiple recurrent keratoacanthoma.

INTRODUCTION

Keratoacanthoma (KA) is a cutaneous neoplasm characterized by rapid growth [1]. The exact incidence of KA is probably underestimated [2]. It is assumed that KA originates from hair follicle [3, 4]. Multiple KA is a rare entity and can be familial or sporadic [2]. Many options are available to treat keratoacanthoma. The recommended option for the majority of cases is excisional surgery. However, it may be associated with several complications including cosmetic and functional problems [1]. The first-line treatment for variants of multiple KA is systemic acitretin or other retinoids [5, 6]. Herein, we report a case of multiple KA who treated by Acitretin and responded well to the drug.

CASE REPORT

A 64-year-old man presented with hyperkeratotic papules that initially appeared on the dorsum of his hand and slowly progressed to form a large annular plaque along with multiple small keratotic plaques and papules. He was depressed and worried about the appearance and his lesions. He had multiple surgery on the lesions that had recurrence and finally the surgeon decided to perform an extensive excision with flap that had recurrence on the donor and recipient site too. Cutaneous examination showed multiple annular, hyperkeratotic plaque on the leg and hands (Fig 1).

Tissue periodic acid-Schiff (PAS) and Fite stains were negative for concomitant microorganisms.

Histological examination of a punch biopsy performed on a papulokeratotic border showed an exoendophytic lesion with an invaginating mass of keratinizing, well-differentiated

squamous epithelium at the sides and bottom of the lesion. There was a central keratin-filled crater. The component cells had a distinctive eosinophilia due to their cytoplasm and epithelial atypia and mitoses were not seen (Fig 2).

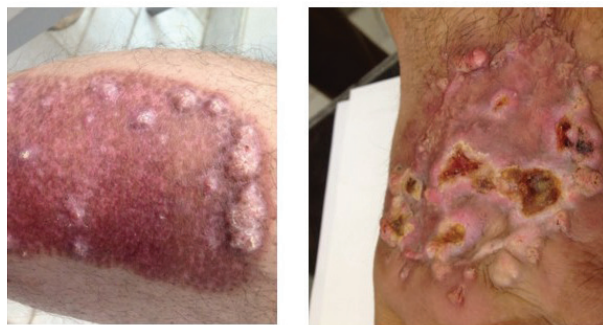

Figure 1: Multiple Hyperkeratotic Papules and Crateriform Nodules on the Graft Site

After correlation of clinical and histopathological findings, the diagnosis of keratoacanthoma was made. Treatment with oral 25 mg/d of Etretinate was started. After 30 days, the effect was obvious: evolution of new lesions had decreased and stable lesions had begun to regress. This dose was continued for 4 months. The lesions became smaller and flattened, and some of them completely disappeared without scars (Fig 3).

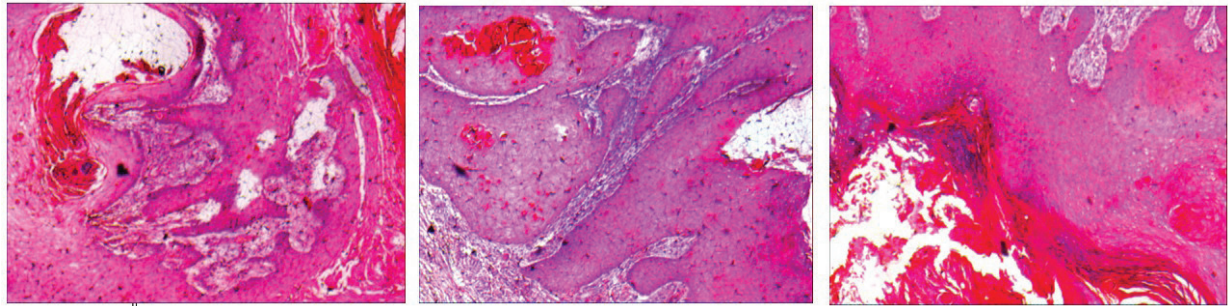


Figure 2: Histologic Section of Lesions on the Hands

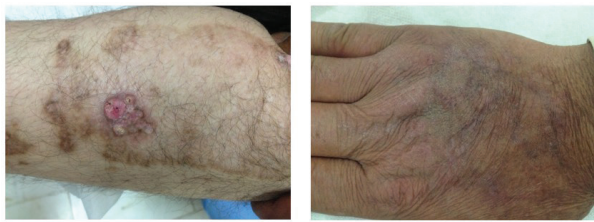

Figure 3: The Disappearance of the Lesions after Acitretine Therapy

DISCUSSION

Keratoacanthoma (KA) is a common neoplasm characterized by rapid growth with potential for tissue destruction and in most cases spontaneous regression. There are two types including simple multiple types. Multiple KAs are quite rare. Multiple types have been reported in the context of rare condition such as Gzybowski eruption keratoacanthoma, KAs of Ferguson Smith type and multiple persistent KAs. The tendency toward spontaneous regression suggests a benign course, but it may rarely metastasize [3]. Solitary KA has three distinct stages: proliferation, maturation, and spontaneous involution [7]. Although the exact etiology is unknown, sun exposure, mechanical trauma, ionizing radiations, chemical carcinogens, infections by human papilloma virus, genetic and immunological, immunosuppressive therapy and chronic inflammation related to some dermatologic disorders such as hypertrophic lichen planus or psoriasis has been suggested to play an etiological role [8-10]. Several reports describe reactive KAs developing after dermatologic surgery, including Mohs surgery, laser resurfacing, radiation therapy, and skin grafting [11-13]. The treatment of choice for solitary type of KA is surgical excision with histopathological verification of the diagnosis, several other therapeutic options such as intraregional injections of interferon alpha, Methotrexate or Bleomycin [14], topical 5-fluorouracil (5-FU) [15], superficial x-ray therapy [16] and systemic retinoid [17] have been reported to be effective, if surgery is not possible. Herein, we presented a new case of multiple KA with no signs of spontaneous regression along with multiple recurrence after surgery that was responsive to Acitretin.

Although the gold standard for the treatment of keratoacanthoma is surgical excision, oral retinoid can be a good choice for multiple recurrent keratoacanthoma.

ACKNOWLEDGMENTS

There is no acknowledgment.

CONFLICTS OF INTEREST

There is no conflict of interest.

FUNDING

There is funding for the present study.

AUTHORS' CONTRIBUTIONS

Narges Ghanei visited the patient and collected data and wrote primary draft, Fariba Binesh presented the pathology report and Mojtaba Babaei Zarch wrote primary draft, revised and submitted it.

REFERENCES

- Rambhia SH, Rambhia KD, Gulati A. A rare case of multiple keratoacanthomas treated with oral acitretin and intralesional methotrexate. *Indian Dermatol Online J.* 2016;7(4):321-3. DOI: [10.4103/2229-5178.185480](https://doi.org/10.4103/2229-5178.185480) PMID: [27559516](https://pubmed.ncbi.nlm.nih.gov/27559516/)
- Kwiek B, Schwartz RA. Keratoacanthoma (KA): An update and review. *J Am Acad Dermatol.* 2016;74(6):1220-33. DOI: [10.1016/j.jaad.2015.11.033](https://doi.org/10.1016/j.jaad.2015.11.033) PMID: [26853179](https://pubmed.ncbi.nlm.nih.gov/26853179/)
- Schwartz RA. Keratoacanthoma: a clinico-pathologic enigma. *Dermatol Surg.* 2004;30(2 Pt 2):326-33; discussion 33. PMID: [14871228](https://pubmed.ncbi.nlm.nih.gov/14871228/)
- Schwartz RA. Keratoacanthoma. *J Am Acad Dermatol.* 1994;30(1):1-19; quiz 20-2. PMID: [8277007](https://pubmed.ncbi.nlm.nih.gov/8277007/)
- Kaźmierowski M, Bowszyc-Dmochowska M. Multiple keratoacanthomas treated with cryosurgery and retinoids. *Postepy Dermatol (Poznan).* 1997;14:397-402.
- Street ML, White JW, Jr., Gibson LE. Multiple keratoacanthomas treated with oral retinoids. *J Am Acad Dermatol.* 1990;23(5 Pt 1):862-6. DOI: [10.1016/0190-9622\(90\)70305-2](https://doi.org/10.1016/0190-9622(90)70305-2) PMID: [2254471](https://pubmed.ncbi.nlm.nih.gov/2254471/)
- Karaa A, Khachemoune A. Keratoacanthoma: a tumor in search of a classification. *Int J Dermatol.* 2007;46(7):671-8. DOI: [10.1111/j.1365-4632.2007.03260.x](https://doi.org/10.1111/j.1365-4632.2007.03260.x) PMID: [17614793](https://pubmed.ncbi.nlm.nih.gov/17614793/)
- Lain EL, Markus RF. Early and explosive development of nodular basal cell carcinoma and multiple keratoacanthomas in psoriasis patients treated with cyclosporine. *J Drugs Dermatol.* 2004;3(6):680-2. PMID: [15624753](https://pubmed.ncbi.nlm.nih.gov/15624753/)
- Allen JV, Callen JP. Keratoacanthomas arising in hypertrophic lichen planus. A case report. *Arch Dermatol.* 1981;117(8):519-21. PMID: [7259250](https://pubmed.ncbi.nlm.nih.gov/7259250/)
- Paul MA, Stonecipher MR, Abernethy J, Leshin B, White WL, Jorizzo JL. Multiple keratoacanthomas in hypertrophic lichen planus: treatment with systemic retinoids (etretinate). *J Eur Acad Dermatol Venereol.* 1994;3(3):320-5. DOI: [10.1111/j.1468-3083.1994.tb00369.x](https://doi.org/10.1111/j.1468-3083.1994.tb00369.x)
- Goldberg LH, Silapunt S, Beyrau KK, Peterson SR, Friedman PM, Alam M. Keratoacanthoma as a postoperative complication of skin

- cancer excision. *J Am Acad Dermatol.* 2004;50(5):753-8. DOI: [10.1016/j.jaad.2003.11.065](https://doi.org/10.1016/j.jaad.2003.11.065) PMID: [15097960](https://pubmed.ncbi.nlm.nih.gov/15097960/)
12. Hadley JC, Tristani-Firouzi P, Florell SF, Bowen GM, Hadley ML. Case series of multiple recurrent reactive keratoacanthomas developing at surgical margins. *Dermatol Surg.* 2009;35(12):2019-24. DOI: [10.1111/j.1524-4725.2009.01327.x](https://doi.org/10.1111/j.1524-4725.2009.01327.x) PMID: [19758354](https://pubmed.ncbi.nlm.nih.gov/19758354/)
 13. Chesnut GT, Maggio KL, Turiansky GW. Letter: Re: Case series of multiple recurrent reactive keratoacanthomas developing at surgical margins. *Dermatol Surg.* 2011;37(6):884-5. DOI: [10.1111/j.1524-4725.2011.01962.x](https://doi.org/10.1111/j.1524-4725.2011.01962.x) PMID: [21492306](https://pubmed.ncbi.nlm.nih.gov/21492306/)
 14. de la Torre C, Losada A, Cruces MJ. Keratoacanthoma centrifugum marginatum: treatment with intralesional bleomycin. *J Am Acad Dermatol.* 1997;37(6):1010-1. DOI: [10.1016/s0190-9622\(97\)70089-6](https://doi.org/10.1016/s0190-9622(97)70089-6) PMID: [9418780](https://pubmed.ncbi.nlm.nih.gov/9418780/)
 15. Yuge S, Godoy DA, Melo MC, Sousa DS, Soares CT. Keratoacanthoma centrifugum marginatum: response to topical 5-fluorouracil. *J Am Acad Dermatol.* 2006;54(5 Suppl):S218-9. DOI: [10.1016/j.jaad.2005.07.023](https://doi.org/10.1016/j.jaad.2005.07.023) PMID: [16631944](https://pubmed.ncbi.nlm.nih.gov/16631944/)
 16. Brusino N, Corradini D, Campolmi P, Massi D, Palleschi GM. Superficial radiotherapy for multiple keratoacanthomas. *Dermatol Ther.* 2014;27(3):163-7. PMID: [25032245](https://pubmed.ncbi.nlm.nih.gov/25032245/)
 17. Aydin F, Senturk N, Sabanciler E, Canturk MT, Turanli AY. A case of Ferguson-Smith type multiple keratoacanthomas associated with keratoacanthoma centrifugum marginatum: response to oral acitretin. *Clin Exp Dermatol.* 2007;32(6):683-6. DOI: [10.1111/j.1365-2230.2007.02498.x](https://doi.org/10.1111/j.1365-2230.2007.02498.x) PMID: [17714527](https://pubmed.ncbi.nlm.nih.gov/17714527/)